



INTERNATIONAL MEDICAL SCIENTIFIC JOURNAL

# **ART OF MEDICINE**



Founder and Publisher **North American Academic Publishing Platforms**

**Internet address:** <http://artofmedicineimsj.us>

**E-mail:** [info@artofmedicineimsj.us](mailto:info@artofmedicineimsj.us)

**11931 Barlow Pl Philadelphia, PA 19116, USA +1 (929) 266-0862**

## **CHIEF EDITOR**

Dr. Pascual Izquierdo-Egea

## **EDITORIAL BOARD**

Prof. Dr. Francesco Albano

Prof. Dr. Tamam Bakchoul

Dr. Catherine J. Andersen

Prof. Dr. Pierre-Gregoire Guinot

Prof. Dr. Sandro Ardizzone

Prof. Dr. Rainer Haak

Dr. Dmitriy Atochin

Prof. Henner Hanssen

Prof. Dr. Antonio Aversa

**Available at** <https://www.bookwire.com/>

**ISBN:** [978-0-578-26510-0](https://www.isbn-international.org/product/9780578265100)

## **EXPERIENCE IN INTRODUCING INTO CLINICAL PRACTICE A METHOD FOR ONE-STAGE ELIMINATION OF CICATRICAL DEFORMITIES IN PATIENTS WITH CONSEQUENCES OF BURNS OF THE FOREARM, BACK OF THE HAND, FINGERS WITH SYNDACTYLS.**

**Madazimov Madamin Muminovich**

Doctor of Medical Sciences, Professor Department of Faculty and Hospital Surgery  
Andijan State Medical Institute  
[komil-madazimov@inbox.ru](mailto:komil-madazimov@inbox.ru)

**Askhanov Zafarbek Pattakhonovich**

Basic doctoral student Department of Faculty and Hospital Surgery Andijan State  
Medical Institute  
[surger\\_askhanov87@mail.ru](mailto:surger_askhanov87@mail.ru)

**Temirov Pulat Chuyanovich**

Assistant of the Department of Faculty and Hospital Surgery Andijan State Medical  
Institute  
[surger\\_temirov@mail.ru](mailto:surger_temirov@mail.ru)

**Khabibullaev Asilbek Pattakhonovich**

Assistant Department of Faculty and Hospital Surgery Andijan State Medical  
Institute  
[surger\\_askhanov87@mail.ru](mailto:surger_askhanov87@mail.ru)

**Abstract:** In one-stage recovery of cicatricial deformities of the forearm, back of the hand, fingers with syndactyly, the most effective is plastic surgery of the forearm, back of the hand with one wide full-layer skin graft after preliminary restoration of the interdigital commissures with  $\Pi$ -shaped patches. This method operated 103 patients. Long-term results were studied in 97 (94.2%) of 103 patients. In 91 (93.8%) patients, good functional and aesthetic results were obtained. Satisfactory results were achieved in 6 (6.2%) patients. In the control group, good results were noted in 31 (36.5%) of 85 patients, satisfactory - in 40 (47%) patients. In 14 (16.5%) patients, the results were considered unsatisfactory.

**Keywords:** scar, burn consequences, one-stage elimination, syndactyly,  $\Pi$ -shaped flap, full-thickness graft.

**Introduction.** With extensive burns, occupying more than 30% of the body surface, there are always burns of the hands (1,5).

Hand burns account for 5.1-6.5% of injuries. Deformations of the hand after burns occur in 40-50% of patients, in 22.5% of cases they become the cause of disability. Therefore, one of the most urgent and complex problems of rehabilitation of burnt patients is the restoration of hand function (2,4).

The complex anatomical structure and function, the variety of developing changes in the form of flexion contractures of the fingers, damage to the extensor tendon apparatus, as well as cicatricial deformity of the dorsal surface of the hand, complicated by extensor contractures of the joints, combined with cicatricial

syndactyly, are the cause of unsatisfactory results. treatment. After the applied traditional methods of surgical treatment, there is a significant number of relapses (4.6).

Until now, such issues as the timing of surgical intervention for post-burn deformities of the hand, its volume, the optimal thickness of transplanted skin grafts have not been adequately resolved; simultaneous elimination of multiple lesions, as well as the features of the operation on the dorsum of the hand in the presence of flexion contracture of the fingers, cicatricial or tendon.

Thus, the aim of the study is to improve the cosmetic results of the operation, as well as to reduce postoperative complications that worsen the functional and cosmetic result and engraftment of the flap.

**Materials and methods.** In order to study the effectiveness of the method of surgical treatment of cicatricial deformity in patients with the consequences of burns of the forearm, back of the hand, fingers with syndactyly, the results of treatment in 188 patients with this pathology (96 women and 92 men) aged 17 to 61 years old, who were hospitalized, were analyzed. treatment in the Department of Reconstructive Surgery of the Andijan Multidisciplinary Medical Center in 2010-2022.

Patients were divided into two groups according to the type of surgical treatment. The main group included 103 patients operated by this technique.

The control group included patients (85) who were operated on by removing the dorsum of the hand using a split autodermal graft.

Patients of the main and control groups underwent identical studies, including: complete blood count, general urinalysis, ECG, biochemical blood tests, PTI, blood clotting time, RW, Hbs-antigen.

To solve the problem by eliminating cicatricial deformities in patients with the consequences of burns of the forearm, back of the hand, fingers with syndactyly, radical excision of scars from below the anterior 1/3 of the metacarpus to the commissure of the interdigital fold, as well as the back surface of the fingers was taken. From the palmar unaffected leaf of the interdigital fold, U-shaped skin-fat flaps are cut out. The wound is closed with a full thickness skin graft.

This study allows the surgeon to correctly choose the tactics of surgical intervention before surgical treatment, and after surgical treatment to assess the viability of the transplanted or displaced flap. In our studies, the temperature of the normotrophic scar showed 36.7°C, that of the atrophic scar - 35.7°C, with the hypertrophic one these figures increased to 38.3°C. This means that the choice of tactics of surgical treatment changes its features.

On normotrophic scars during surgery, the intermediate layer is easily dissected, which makes it possible to clearly determine the lines of scars from healthy tissue. Scars are excised without blood loss. At the final stage of the operation, the surgeon evenly sutures. We studied the temperature of soft tissues in the transplanted or displaced flaps, as well as the suture lines in the first, third, seventh, fourteenth and twenty-first days before, during and after the operating periods. On the first day of the postoperative period, these figures decreased to 35.8°C, after the third day it rose, and on the seventh day it returned to normal. On the lines of scars, these figures rose

to 38°C. This is due to the fact that the blood supply to the suture line is two-way, so the blood flow is not restored in the early stages, but after 14 days the healing time is accelerated.

On atrophic scars during surgery, the intermediate layer is very thin and does not allow a clear definition of the lines of excision of the scar without blood loss. Further, during the operation, it does not allow the surgeon to evenly suture, often the sutures perforate the scar tissue. In the postoperative period, tissue temperature indicators in transplanted or displaced flaps were studied on the first, third and seventh days. On the first day of the postoperative period, these indicators decreased to 35.8°C, after the third day it rose, and on the seventh day it returned to normal.

On hypertrophic scars during surgery, the intermediate layer is not defined and does not provide a clear orientation to the line of excision of the scar with blood loss. Further, during the operation, it does not allow the surgeon to evenly suture, often the sutures perforate the scar tissue. In the postoperative period, tissue temperature indicators in transplanted or displaced flaps were studied on the first, third and seventh days. On the first day of the postoperative period, these indicators decreased to 38.2°C, on the third and seventh days it did not decrease, only after the tenth day the temperature indicators decreased to a normal level. But until the fourteenth day, the edema in the hands remained.

To evaluate the effectiveness of the proposed scheme of the developed methods, the dynamics of transcutaneous partial pressure was studied using the method of the closest analogue according to the criteria:

1. Oxygen consumption in mixed and transplanted flaps in the oxidation of endogenous substrates.

2. Microcirculation in mixed and transplanted flaps.

Thanks to the possibility (polarograph PU-1 (RB)) the oxygen velocity in the tissues of the state of energy exchange of mixed and free flaps was studied during the oxidation of endogenous substrates  $V_{end}$ .

The rate of oxygen consumption during oxidation of endogenous substrates in mixed and free flaps ( $V_{end}$ ) in the main group was  $2.16 \pm 0.14$  nmol O<sub>2</sub>/min/min/mg of protein, while in the control group it was slightly higher ( $2.27 \pm 0.43$  nmol O<sub>2</sub>/min/min/mg of protein). ( $p > 0.05$ ).

To improve the quality of the postoperative result, in the form of the viability of the transplanted or displaced flap, we performed percutaneous oximetry. Studies have shown changes in the dynamics of the transcutaneous partial pressure of oxygen (PtcO<sub>2</sub>) in a normotrophic scar 86.7 mm Hg, in an atrophic scar - 82 mm Hg, and in a hypertrophic scar - 93.1 mm Hg. As can be seen from the indicators of the normotrophic scar, it is closer to healthy tissue.

#### **Indicators of transcutaneous oxygen partial pressure.**

On normotrophic scars before, during and after surgery on the first, third and seventh days, the indices of oxygen partial pressure in tissues were studied. On the first day at the end of the displaced and free flaps, these indicators decreased slightly to 85 mm Hg, and on the third and seventh days it decreased to normal values.

On atrophic scars before, during and after surgery, the indicators of transcutaneous oxygen partial pressure in tissues, transplanted or displaced flaps on the first, third and seventh days were studied. On the first day of the postoperative period, these figures decreased to 80 mm Hg, after the third day it rose, and on the seventh day it returned to normal.

On hypertrophic scars before, during and after surgery, the indicators of transcutaneous oxygen partial pressure in tissues, transplanted or displaced flaps on the first, third and seventh days were studied. On the first day of the postoperative period, these indicators decreased to 80 mm Hg, on the third and seventh days it did not decrease, only after the tenth day, the indicators of transcutaneous partial pressure of oxygen in the tissues.

**Results.** The features of the distinctive part of the claims provide a solution to the problem as follows.

Under general anesthesia, scars are excised radically strictly along the intermediate layer from below the anterior 1/3 of the metacarpus to the commissure of the interdigital fold, as well as the back surface of the fingers. U-shaped skin-fat flaps were cut out from the palmar unaffected leaf of the interdigital fold, lateral surfaces of the proximal phalanges and the palm. The free ends of the flaps were fixed with two sutures into the depression between the heads of the metacarpal bones, forming interdigital commissures.

Using a scalpel, wide skin grafts are taken from the upper 1/3 of the anterior lateral femoral region and close the wound starting from below the anterior 1/3 of the metacarpus. In the area of the U-shaped flap and between themselves, the grafts were sutured with interrupted atraumatic sutures. The donor wound is sutured with interrupted sutures.

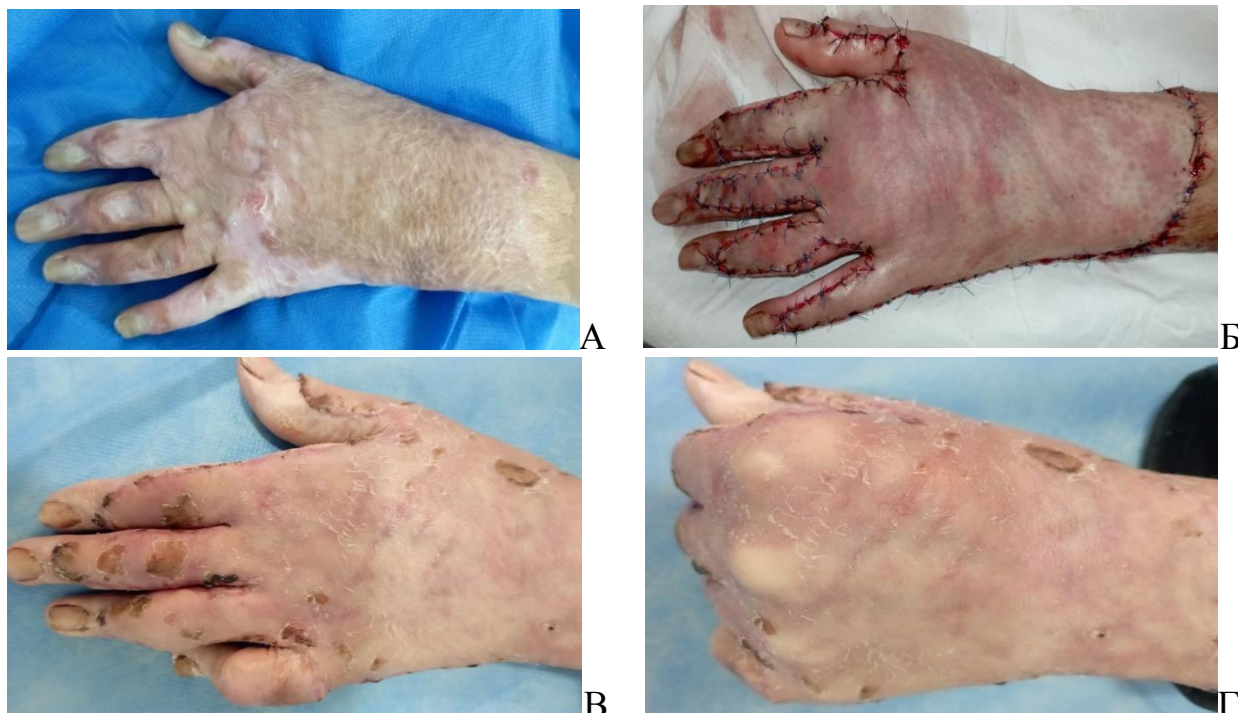
The first dressing was performed 5-7 days after the operation. At the same time, hematomas present in some areas under the grafts were released through small incisions above them with a scalpel.

Wide skin grafts with U-shaped flaps take root well. In the long term, grafts take the form of normal skin, become elastic, soft, easily taken into a fold, and provide normal movements in the joints of the hand.

**Clinical example:** Patient Sh. 1988, Case history No. 544/232. Date of injury - 2019. Diagnosis: Post-burn cicatricial deformities of the back of the left hand with syndactyly I-II, II-III, III-IV, IV-V interdigital spaces and the wrist joint (Fig. 1).

Operation No. 198 - simultaneous elimination of cicatricial deformity of the dorsum of the left hand in the area of the wrist joint with syndactyly of the interdigital spaces using combined plasty.





**Rice. 1.** Patient Sh. 1988. Case history no. 544/232.

A: Post-burn cicatricial deformities below the anterior 1/3 of the metacarpus of the wrist joint, the back of the left hand with syndactyly I-II, II-III, III-IV, IV-V interdigital spaces. B: Scars were excised below the anterior 1/3 of the metacarpus of the wrist joint, the back of the left hand with syndactyly, and the wound was closed with a full-thickness skin graft. C, D: The result of plastic surgery.

Patients of both groups observed a single general regimen and diet.

All patients in the postoperative period received a standard complex of drug therapy: biostimulants, vitamin therapy, antibiotics, local magnetic therapy from the 3rd postoperative day.

The criteria for evaluating the results of surgical treatment of the consequences of burns on the dorsum of the hand were: subjective assessment of the condition (aesthetic and functional) from the words of the patients themselves and the people around them and an objective assessment of the condition of the reconstructed hand in comparison of photographs before the burn injury, before and after the operation, respectively.

Reconstructive plastic surgery of a post-burn injury had practically no effect on improving the function of the fingers in the form of extension and flexion.

Long-term results were studied in 97 (94.2%) of 103 patients. In 91 (93.8%) patients, good functional and aesthetic results were obtained. Satisfactory results were achieved in 6 (6.2%) patients.

After simultaneous elimination of the deformity in two (2%) patients with the consequences of burns of the forearm, back of the hand, fingers with syndactyly, focal graft lysis occurred in the postoperative period due to the formation of a hematoma under it. In none of the cases, we noted necrosis of U-shaped flaps and recurrence of syndactyly.

In the control group, good results were noted in 31 (36.5%) of 85 patients, satisfactory - in 40 (47%) patients. In 14 (16.5%) patients, the results were considered unsatisfactory.

The subjective assessment of patients and the people around them was considered very important. In order to establish the assessment, all patients were interviewed at different times of the postoperative period. According to the patients, their psycho-emotional state has significantly improved. After the operation, all unwanted inconveniences were eliminated, they began to feel much more confident in public places, at work, and they began to hide their hands less because of deformed fingers, which testified to the effectiveness of the surgical treatment.

**Conclusion.** Analysis of the obtained results shows that the main group achieved the best aesthetic and functional effect compared to the control group. This lies in the fact that in all patients, postoperative scars healed with more gentle scarring, there were no postoperative complications from the wound.

### References

1. Azolov V.V., Alexandrov N.M., Petrov S.V. 2000, New aspects of the use of percutaneous devices in surgery for severe consequences of thermal hand injury// Mater. International Conf. "Actual problems of thermal injury", devoted to. 70th Anniversary of the Research Institute of Emergency Medicine. I.I. Dzhanelidze and the 55th anniversary of the burn center. June 27-29, 2002 - St. Petersburg, 2002. - P.403-405.
2. Ruchin M.V. Restoration of the function and anatomical integrity of the structures of the musculoskeletal system in patients with deep burns: Abstract of the PhD thesis. Nizhny Novgorod, 2019. - 13 p.
3. Sarygin P.V. and others. Surgical treatment of post-burn hand defects: Annals of Surgery, No. 3, 2015. – P.38.
4. Filippova O.L. Surgical and morphological aspects of the treatment of cicatricial deformities in children: Abstract of the DSc thesis. - St. Petersburg 2015. - 14 p.
5. Liu J.C., Wang L.N., Chen F.S. Experience of application of skin flap in repairing 112 patients with severe thermo pressure injury of hand// Zhongguo Xiu Fu Chong Jian Wai Ke Za Zhi. -2000.- Vol. 14(4).- P. 197-99.
6. Rochet J.M, Zaoui A. Burn scars: rehabilitation and skin care //Rev. Prat.-2002.- Vol.52(20).- P.2258-63.