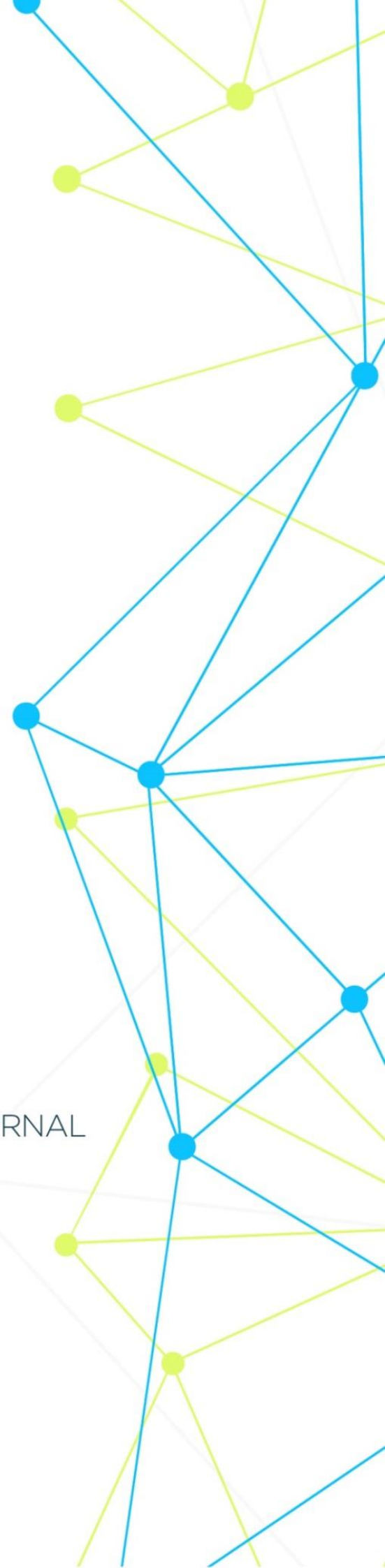


INTERNATIONAL MEDICAL SCIENTIFIC JOURNAL

ART OF MEDICINE



Art of Medicine
International Medical Scientific Journal
Founder and Publisher **North American Academic Publishing Platforms**
Internet address: <http://artofmedicineimsj.us>
E-mail: info@artofmedicineimsj.us
11931 Barlow Pl Philadelphia, PA 19116, USA +1 (929) 266-0862

Volume-3
Issue-1

Chief Editor

Dr. Pascual Izquierdo-Egea
Prof. Dr. Francesco Albano
Dr. Catherine J. Andersen
Prof. Dr. Sandro Ardizzone
Dr. Dmitriy Atochin
Prof. Dr. Antonio Aversa
Prof. Dr. Tamam Bakchoul
Prof. Dr. Pierre-Grégoire Guinot
Prof. Dr. Rainer Haak
Prof. Henner Hanssen
Roy G. Smith
Department of Molecular and Cellular Biology/Department of Medicine
Baylor College of Medicine
Houston, TX 77030, USA
Kalpesh Patel, MD
The Sydney Kimmel Comprehensive Cancer Center
Johns Hopkins Medical Institutions
Baltimore, MD, 21231, USA
Roy G. Smith
Department of Molecular and Cellular Biology/Department of Medicine
Baylor College of Medicine
Houston, TX 77030, USA
Khamdamov Bakhtiyor Bukhara State Medical Institute
Khamdamova Mukhayokhon Bukhara State Medical Institute

Available at <https://www.bookwire.com/>
ISBN: [978-0-578-26510-0](https://www.isbn-international.org/product/9780578265100)

CURRENT PROBLEMS OF MORPHOLOGICAL DIAGNOSIS OF BREAST FIBROADENOMAS IN WOMEN

Yuldashev Bakhrom Sobirdzhanevich

Urgench Branch Tashkent Medical Academy

Abstract: The growth of fibroadenomas is thought to be estrogen-dependent: however, none of the steroid hormone receptors acting on breast tissue have been shown to cause fibroepithelial damage in the breast stroma. This article examines estrogen receptor (ER)- α and - β expression in fibroadenomas and benign, three-borderline, and malignant phyllodes tumors by immunocytochemistry. All of these scans revealed spindle-shaped cells and one distant metastasis.

Keywords: (ER)- α , - β , fibroadenomas.

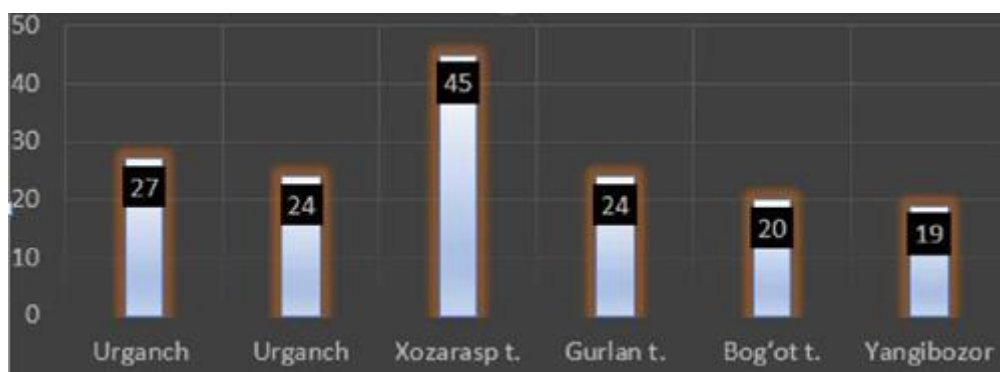
Relevance of the topic: Mammary gland fibroadenoma and phyllodes tumor are characterized by bilateral lesions and proliferation in both epithelial and stromal parts of the terminal duct unit. Proliferation of stromal cells is usually the main event, followed by proliferation of secondary epithelial cells. Although recent studies have shown that stromal cell clonality, low-grade phyllodes tumors are a neoplastic process, most fibroadenomas are the result of hyperplastic processes involving the connective tissue of the lobar (lobular) unit.[5] . The natural history of fibroadenoma varies. They can grow, regress, or remain unchanged when the patient's hormonal background changes, but often stop growing after reaching a diameter of 2-3 cm. In addition, the stroma becomes less cellular with age. and its hyalinization increases [2]. These data (appearance in young women and sclerotic involution in the elderly) indicate hormonal reactivity of fibroadenoma [1]. This hypothesis is confirmed by the recent finding of high levels of estradiol in plasma in patients with fibroadenoma [5,6], single nucleotide polymorphisms of genes encoding enzymes involved in estrogen metabolism were also shown in the same patients. In addition, tamoxifen treatment significantly reduces proliferation activity in the stroma of fibroadenomas. The classical mediator of response to estradiol and tamoxifen is estrogen receptor (ER)- α , but ER- α is mainly expressed by epithelial cells in fibroadenomas and phyllodes tumors, while its expression by stromal cells remains controversial [3,5]. A recent study showed that only ER- β isoforms are present in mammary stromal cells of elderly people. All these data have prompted scientists in this field to investigate the possible expression of ER-P by stromal cells in fibroadenomas and phyllodes tumors [4,5], In addition, recently, general differentiation of smooth muscle cells in mammary fibroepithelial lesions and other estrogen-dependent After observing a high level of ER- β in the muscle cells of the organs, scientists studied the immunophenotype of stromal cells using smooth muscle actin and colponin as markers [5].

Purpose of work. Studying the relationship between dys hormonal diseases in women and fibroadenoma disease.

Material and methods:

RIO and RIATM Khorezm in 2015-2020 branch Polyclinic to the department appeal did outpatient cards of patients and their diseases histories according to

Results: RIO and RIATM Khorezm branch Polyclinic to the department appeal did a total of 515 people women's outpatient cards analysis, 232 of them (45.00%) had fibrosis-cystosis mastopathy (FKM), 159 (30.80%) fibroadenoma (FA), 38 (7.3%) nodular or fibrosis mastopathy (FM), 10 (1.9%) steatonecrosis, 23 (4.4%) papilloma, 18 (3.5%) cysts mastopathy (CM), 21 (4.0%) lipoma, 14 (2.7%) ductectosis diseases was determined. Follow up from 64 (12.4%) patients (rak took processes), 27 (5.2%) malignancy observed , 20 people in the patient dangerous transition possibly top , the remaining 17 people the patient treatment result efficient finished. A total of 159 patients with FA were found in Khazarasp district (45 women) according to fibroadenoma.



We can see the results of 11 patients with malignancy in the table. when divided into age groups in the cross-section of districts below

	18-44	45-59	60-74	75 years	T	%
Urganch the city	5	5		1	1	40
Urganch district			1		1	3.7
Honka district	2				2	7.
Khozarasp turn	2	4		1	7	25
Bogot district	2		1		3	11
New market tour	1		2		3	11
Total	12	9	4	2	T	
In percent (%)	44.4	33.4	14.8	7.4	1	10

According to the localization, it was observed in 10 (37%) patients in the right mammary gland, 16 (59.2%) in the left mammary gland, and 1 (3.7%) in both mammary glands. This is malignancy has been fibroadenoma disease in 11 patients (40.8%). with one how many years treated walked.

Malignancy the term seeing coming out 1 person for 1 month 3 patients in 3 months 2 patients in 6 months patient , 7 patients in 1 year , 1 patient in 2 years , 2 patients in 3 years patient , 2 in 4 years the patient found in 8 cases malignancy term not identified.

11 had fibroadenomas of patients treatment is work stages learning result below

It's bad good quality to the tumor 27 people who became of the patient from biopsy received materials histological checking When we see, the corridor ichi cancer in citu in 1 case, corridor invasive tumor in 5 cases, corridor infiltrator tumor in 6 cases , adenocarcinoma in 8 cases, lumped carcinoma in 3 cases, corridor infiltrator carcinoma in 6 cases, corridor non-infiltrating In the case of cancer , it is invasive nonspecific cancer in 2 cases and cirrhosis type in 1 case with was determined.

Patients TNM classification of disease stages comparing in our study , TNM - in 8 (29.6%) patients , $T_2 N_0 M_0$ - in 5 (18.5%) patients , $T_2 N_1 M_0$ - in 5 (18.5%) patients , $T_2 N_3 M_0$ - 1 (3.7%) patients , $T_2 N_1 M_1$ - 3 (11.7%) patients , TDM_0 - 4 (14.8) patients , $T_{4b} N_{i0}$ - 1 (3.7%) patients was determined.

It can be seen that pre-cancerous diseases of the mammary gland are more common in women aged 18-44, and changes in the hormonal status cause dysplasia of the mammary gland in such women. 27 of the studied women had such changes, and we observed that benign tumors in them became malignant and turned into dangerous tumors. However, this is a very poor indicator, which is 5.2% of all studied patients. 11 of the patients (40.8%) have fibroadenoma, and 18% of them, without starting the treatment on time, miss the late stages. The absence of a normal sex life in the anamnesis of such women, a large number of miscarriages, a large number of abortions, and the presence of persistent inflammatory and cystic diseases in the genitals are of great importance in our scientific work.

In conclusion, to study the mechanisms of proliferation of fibroadenoma in women, the dependence on hormonal status, age (the most young people are 18-44 years old - in 72% of cases), the degree of malignancy of benign tumors, early detection of breast cancer is considered important in detection and prevention, and increased oncological vigilance in polyclinics and primary health care units would serve to prevent widespread cases of the disease among young women.

References

1. "Modern strategy for the prevention of breast cancer". Meshcheryakov A.A. 2017
2. "Intraepithelial neoplasia of the breast." Efremov G.D. 2013
3. "Pathomorphological and immunohistotoxic study of myoepithelia in hyperplastic processes and breast cancer". Ivshina Yu.A 2005
4. Clinical and morphological features of multicentric growth and recurrence in breast cancer. Vtorushin S.V. 2012
5. Estrogen receptor-p is expressed in stromal cells of fibroadenoma and phyllodes tumors of the breast A Sapino 2006 Cited: 91 May 2006 Modern Pathology 19(4):599-606.
6. "Sut bezi saratonini tashxisini kuyish va davolashda klinik-morfologik va molekulyar genetik jixatlari." Kaxxarov A.J. 2019y.