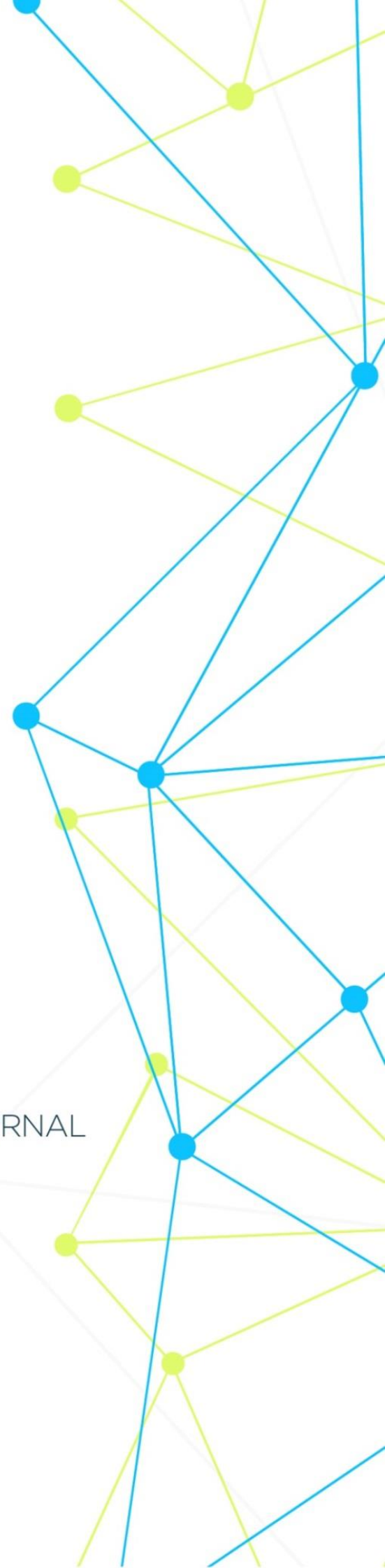


INTERNATIONAL MEDICAL SCIENTIFIC JOURNAL

ART OF MEDICINE



Founder and Publisher **North American Academic Publishing Platforms**

Internet address: <http://artofmedicineimsj.us>

E-mail: info@artofmedicineimsj.us

11931 Barlow Pl Philadelphia, PA 19116, USA +1 (929) 266-0862

Chief Editor

Dr. Pascual Izquierdo-Egea

Prof. Dr. Francesco Albano

Dr. Catherine J. Andersen

Prof. Dr. Sandro Ardizzone

Dr. Dmitriy Atochin

Prof. Dr. Antonio Aversa

Prof. Dr. Tamam Bakchoul

Prof. Dr. Pierre-Grégoire Guinot

Prof. Dr. Rainer Haak

Prof. Henner Hanssen

Roy G. Smith

Department of Molecular and Cellular Biology/Department of Medicine

Baylor College of Medicine

Houston, TX 77030, USA

Kalpesh Patel, MD

The Sydney Kimmel Comprehensive Cancer Center

Johns Hopkins Medical Institutions

Baltimore, MD, 21231, USA

Roy G. Smith

Department of Molecular and Cellular Biology/Department of Medicine

Baylor College of Medicine

Houston, TX 77030, USA

Khamdamov Bakhtiyor Bukhara State Medical Institute

Khamdamova Mukhayokhon Bukhara State Medical Institute

Available at <https://www.bookwire.com/>

ISBN: [978-0-578-26510-0](https://www.isbn-international.org/product/978-0-578-26510-0)

THE ROLE OF IMMUNOPHENOTYPING OF TUMOR CELLS IN THE DIAGNOSIS OF ACUTE LEUKEMIA (case reports)

Abdullaeva N. Sh., Karimov Kh.Y., Boboev K.T., Matkarimova D.S.

Republican Specialized Scientific and Practical Medical Center of Hematology
Uzbekistan, Tashkent

Purpose of the study. Objective: to evaluate the role of immunophenotyping of tumor cells in the diagnosis of ETP-ALL.

Material and methods. The material for the study was patients G., 26 years old and O., 22 years old, who were admitted for examination and inpatient treatment in the 1st and 2nd oncohematological departments of the Republican Specialized Scientific and Practical Medical Center for Hematology (RSNPMCG, Uzbekistan, Tashkent) with a diagnosis of acute leukemia.

The methods included clinical laboratory, immunophenotypic, cytogenetic and instrumental studies.

Conclusion: Early immunophenotyping of blast cells makes it possible to correctly determine the variant of acute leukemia in a timely manner, and, in turn, start individualized targeted PCT, which allows achieving effective results in the treatment of patients with AL.

Keywords: acute lymphoblastic leukemia, ETP-ALL, complete blood count, myelogram, blasts, immunophenotyping.

Introduction. In the structure of all human malignant neoplasms, a heterogeneous group of neoplasias from the hematopoietic system, represented by acute leukemias (AL) is distinguished by the polymorphism and severity of its manifestations [1,6,16].

T-lymphoblastic leukemia (T-ALL) is especially aggressive among OL in adults, accounting for up to 25% of all ALL cases [9]. Despite the timely start of program polychemotherapy (PCT), 40-50% of patients experience a relapse of the disease and the resulting resistance to treatment, even with the use of high-dose newest treatment programs [2,15].

Among all adult cases of T-ALL, an average of 7-8%, with particular difficulties in diagnosis and treatment, there is a separate special subtype of T-ALL with a precursor of early T-cells (ETP - ALL - Early T - cell P recursor) (WHO, 2016) [2,10], which has its own unique genomic and immunophenotypic profile [14]. Patients with this subtype compared with other types have lower event-free (EFS/ EFS) and overall survival (OS/ OS) [3].

It is known from the literature that the immunophenotypic profile of blast cells plays a key role in the diagnosis of ETP-ALL [18]. So, according to Coustan - Smith et al . (2009) in ETP-ALL, the frequency of expression of CD2, superficial CD3, CD4, and CD10 is much less common [7]. Other authors (Zurbier et al ., 2014) found that for ETP-ALL the immunophenotype CD1a - "-", CD4 - "- -" and CD8 - "- -", CD34 - "+" and/or CD13/CD33 - "+" has sensitivity 77% and specificity 94% [19].

Khogeer Research Group et al . (2019) developed a system for assessing ETP-ALL using 11 markers, according to which the presence of expression of surface

CD3 (> 20% of blasts) and CD5 (> 75% of blasts) allows establishing the diagnosis of ETP-ALL [11].

of significant myeloid differentiation in ETP - ALL is fraught with difficulties in differential diagnosis with an undifferentiated variant and a mixed phenotype with T/myeloid phenotype of OL [12,17]. In this connection, the Italian Association of Pediatric Hematology and Oncology (AIEOP-BFM) for the diagnosis of ETP-ALL recommends the determination of a complete panel of monoclonal antibodies with the correct interpretation of the results of flow cytometry, which are necessary conditions for an accurate diagnosis [8].

Taking into account the available research results, two main approaches to the diagnosis of ETP-ALL are currently formed: taking into account the profile of gene expression or the profile of immunophenotyping detected using flow cytometry, which not only diagnoses ETP-ALL, but also determines its origin [5,13].

Thus, performing immunophenotyping using a comprehensive panel of antibodies, among all available classification systems, the classification recommended by WHO seems to be the most acceptable, which includes the most extensive panel of markers, the immunophenotypic criteria of which are confirmed by gene expression profiling at various stages of T-cell development.

The **aim** of this study was to evaluate the role of immunophenotyping of tumor cells in the diagnosis of ETP-ALL.

Material and methods. The material for the study was patients G., 26 years old and O., 22 years old, who were admitted for examination and inpatient treatment in the 1st and 2nd oncohematological departments of the Republican Specialized Scientific and Practical Medical Center for Hematology (RSNPMCG, Uzbekistan, Tashkent) diagnosed with acute leukemia.

Research methods included clinical, standard laboratory (complete blood count (CBC), myelogram, biochemical blood test (BAC), urinalysis (CAM), PCR test for HBs and HCV) examination, as well as flow cytometry, cytogenetic and instrumental methods surveys.

Results and discussion: Clinical example No. 1. Patient G., 26 years old, was admitted on 06/09/2022 with complaints of weakness, lethargy, bone pain, loss of appetite.

From the anamnesis he has been ill for the last 2 months. The disease began acutely with an increase in body temperature to 39 °C, which temporarily decreased against the background of antipyretic and antibiotic therapy prescribed by a doctor at the place of residence. In connection with the deterioration of the general condition of the patient referred to a consultation with a hematologist. During the examination, blast cells were found in the general blood test, after which the patient was referred for diagnosis and treatment at the RSSPMCH.

The patient was admitted in a clear mind, in serious condition due to the underlying disease and its complications in the form of anemic syndrome, without neurological and hemorrhagic syndromes. The skin and visible mucous membranes are pronouncedly pale, clean. All peripheral lymph nodes are enlarged to 2.0 x 2.5 cm. The liver protrudes from under the edge of the costal arch by 2-3 cm, the spleen by 3-4 cm.

In the general blood test: hemoglobin - 58 g / l, erythrocytes - 1.7×10^{12} / l, platelets - 5×10^9 / l, leukocytes - 264×10^9 / l, blast cells - 85%, lymphocytes - 11 %, monocytes - 4%, ESR - 12 mm/h.

In the biochemical analysis of blood and urine, the main indicators are within normal limits. PCR tests for the presence of HBs and HCV antigens are negative.

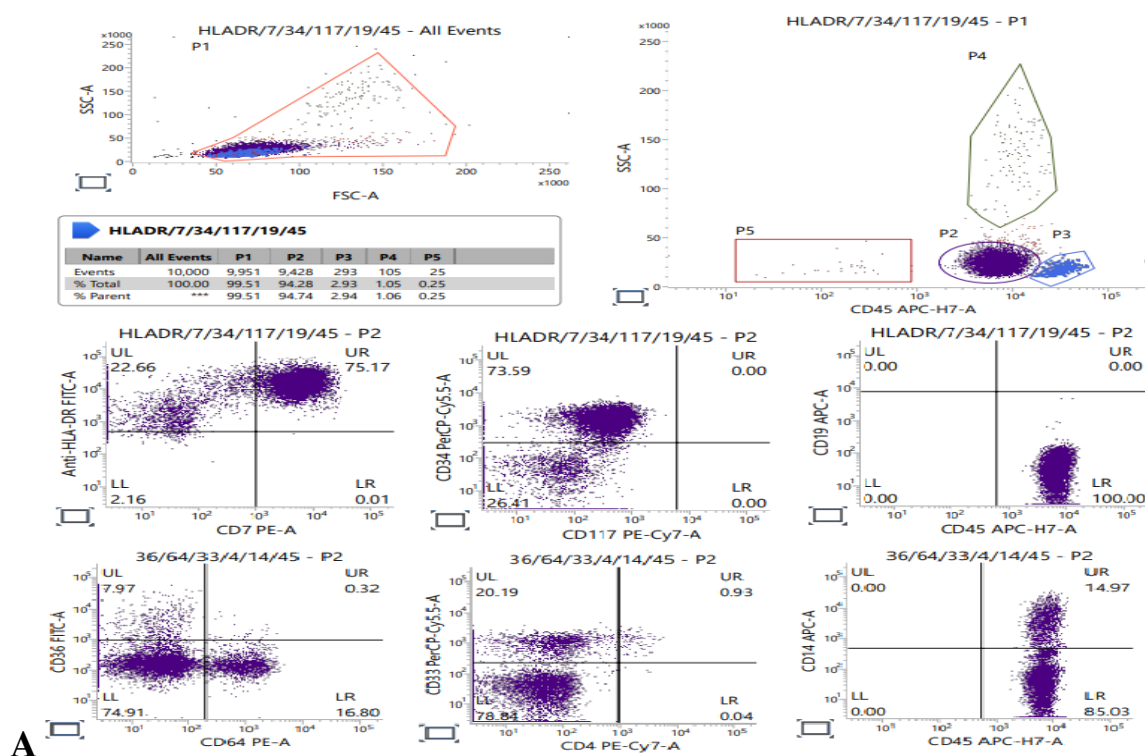
In the myelogram, the bone marrow cellularity is sufficient, the number of blast cells is 98%, megakaryocytes were not detected. Cytochemical examination of a cat brain smear: reaction to myeloperoxidase - "-", to glycogen - "+" coarse granular .

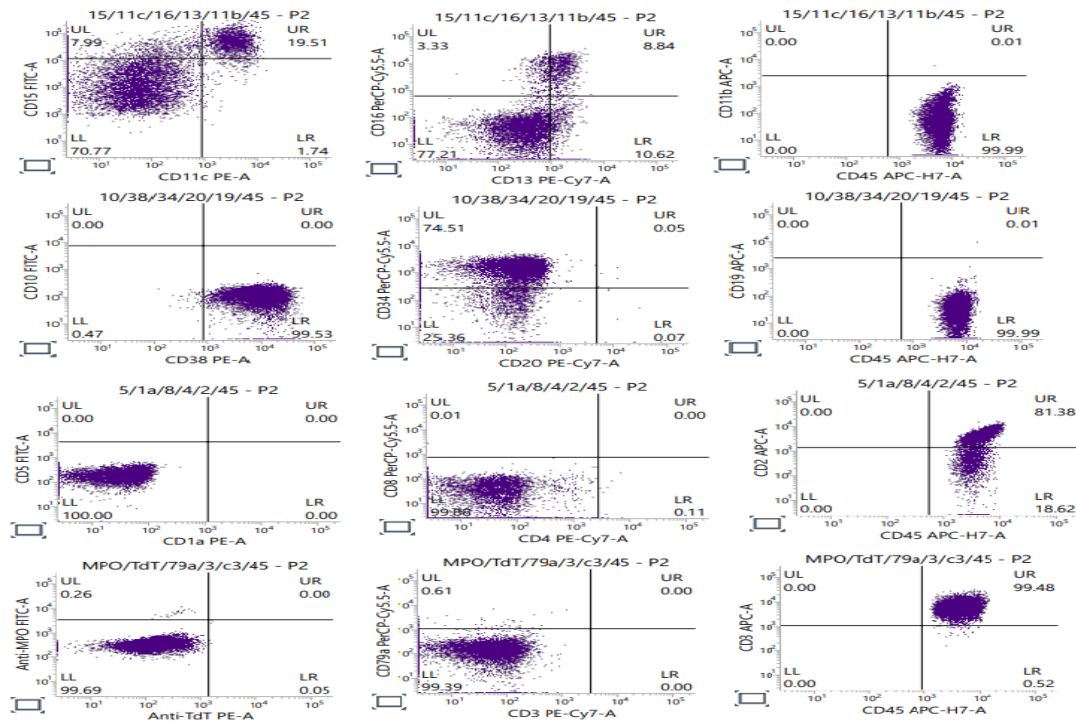
In the bone marrow, 44% of blast cells with positive expression of CD34, CD7, cCD3, CD2, CD117, CD15, CD11c, CD13, CD45, CD38, HLADR were detected by flow cytometry.

According to the EGIL classification (1995) and WHO recommendations [2, 4], this case corresponded to T -ALL with aberrant expression of myeloid markers, while the immunophenotype of blast cells also corresponded to ETP-ALL (Figure 1).

Cytogenetic study revealed the 46,XY karyotype. Translocation t (9:22) was not detected.

Based on the results of the examinations , patient G. (26 years old) was diagnosed with acute T-lymphoblastic leukemia from early T-cell precursors (ETP-ALL).





B

Fig.1. To a clinical example No. 1. The results of immunophenotyping of thieves cells of patient G., 26 years old.

Clinical example No. 2. Patient O., 22 years old, was admitted on 01/07/2022 with complaints of weakness, shortness of breath, headaches, fever up to 38.7C, bruising on the skin of the body and limbs, pain throughout the body, in the bones , lack of appetite.

From the anamnesis she has been ill for the last 3 months. The disease began acutely with the above manifestations. In this connection, she was referred to a hematologist at the place of residence. During the examination, in the general blood test, a decrease in hemoglobin and platelets was found, in the myelogram - blast cells of 10-12%. Acute leukemia was diagnosed and treatment was started, which included antibiotic therapy, blood component replacement and symptomatic therapy. In connection with the deterioration of the general condition over the past week, the patient was referred for diagnosis and treatment at the RSSPMCG.

Upon admission, the patient's consciousness is clear, severe due to the underlying disease and its complications in the form of anemic and hemorrhagic syndrome. The skin and visible mucous membranes are pronouncedly pale, clean. All peripheral lymph nodes are enlarged to 2.0 x 2.5 cm. The liver is of a dense consistency, sensitive, protrudes from under the edge of the costal arch by 7-8 cm, the spleen is of a dense consistency, not sensitive, protrudes from under the edge of the costal arch by 15 cm .

When examined in the general blood test: hemoglobin - 82 g / l, erythrocytes - 2.9×10^{12} / l, platelets - 43×10^9 / l, leukocytes - 210×10^9 / l, blast cells - 36%, myelocytes - 7%, metamyelocytes - 8%, stab neutrophils - 3%, segmented neutrophils - 35%, lymphocytes - 11%, ESR - 55 mm / h.

In the biochemical analysis of blood and urine, the main indicators are within normal limits. PCR tests for the presence of HBs and HCV antigens are negative.

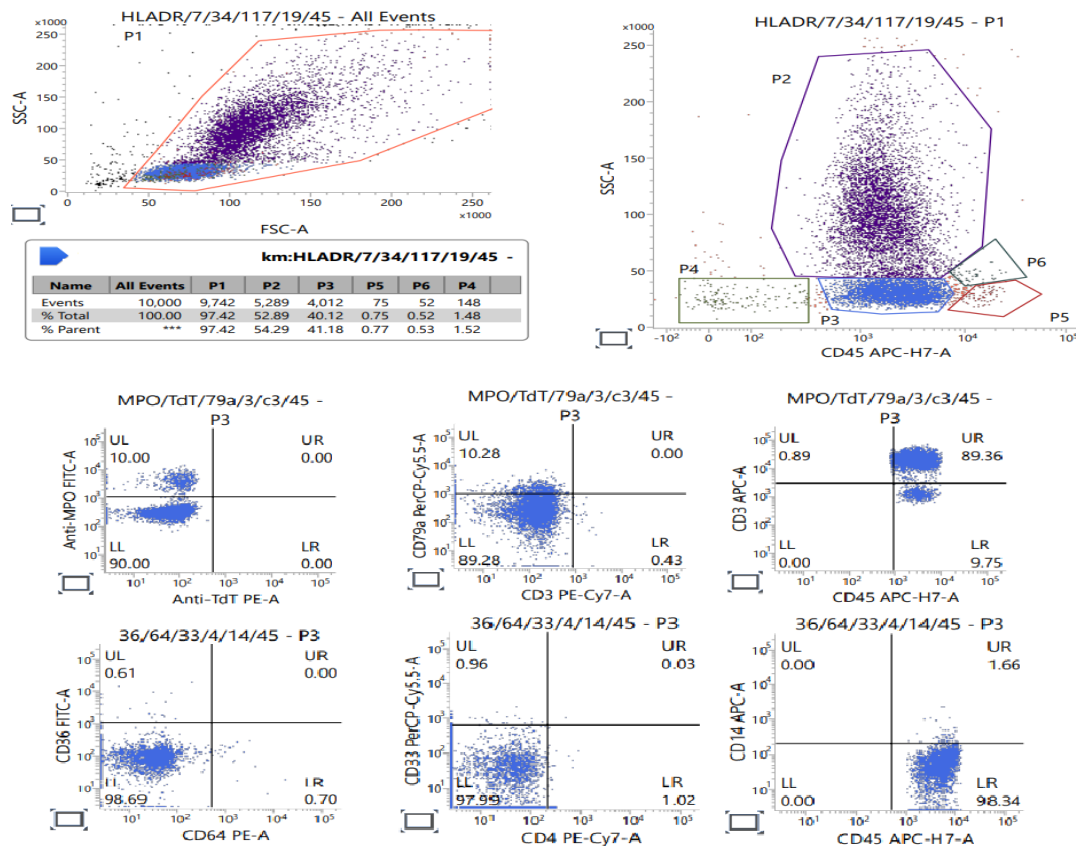
In the myelogram, the erythron is depressed, the number of blast cells is 42.6%, megakaryocytes - 1, lymphocytes - 7.2%. Cytochemical examination of a cat brain smear: reaction to myeloperoxidase - "-", to glycogen - "+" coarse granular .

In the bone marrow, 44% of blast cells with positive expression of CD7+, cCD3+, CD13+, CD2+, CD5+, CD38+, CD117+, CD19+, CD45+ were detected by flow cytometry. Aberrant expression of CD19 and CD117 was observed, the presence of SSC/117 expression was found (35%).

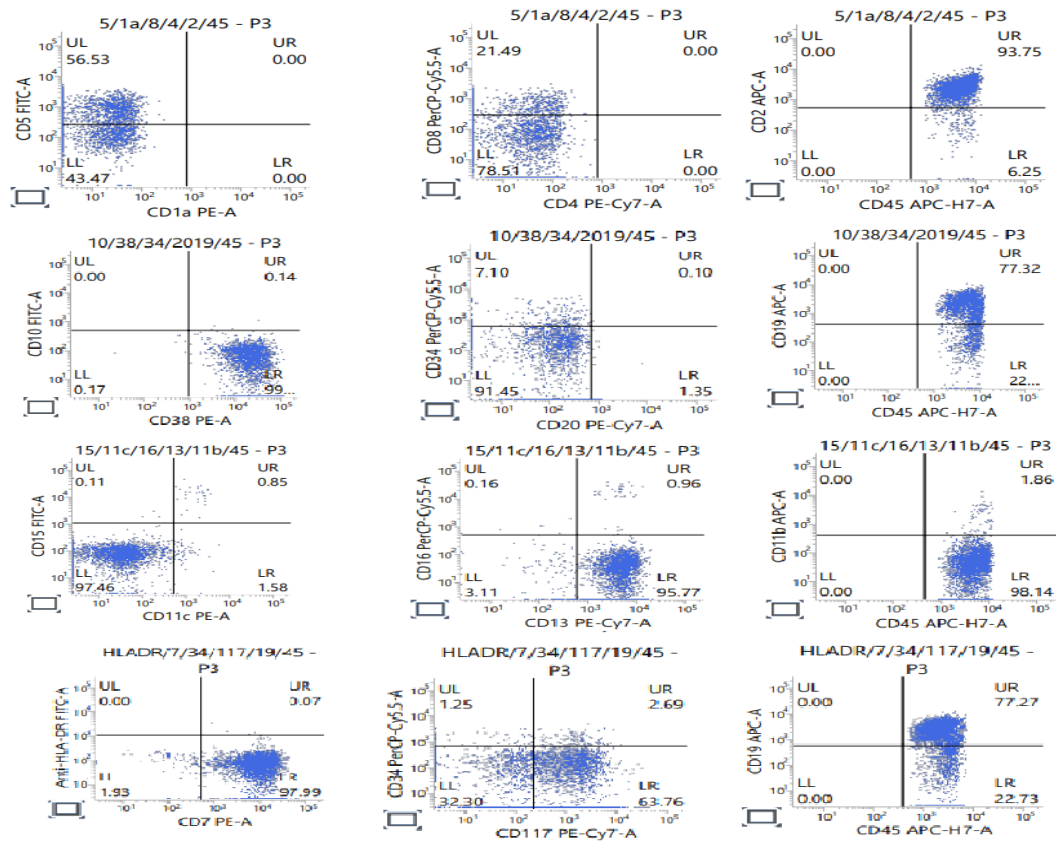
According to the EGIL classification (1995) and WHO recommendations [2, 4], this case corresponded to T -ALL with aberrant expression of myeloid markers, while the immunophenotype of blast cells also corresponded to ETP-ALL (Figure 2).

Cytogenetic study revealed the 46,XX karyotype. Translocation t (9:22) was not detected.

Based on all the results of the examinations, patient O. (22 years old) was diagnosed with acute T-lymphoblastic leukemia from early T-cell precursors (ETP-ALL).



A



B

Rice. 2. Clinical example No. 2. The results of immunophenotyping of thieves' cells of patient O., 22 years old.

Conclusion. Thus, T-ALL, like other variants of OL, is a neoplasia with a complex and not fully understood mechanism of formation. In this connection, to date, the diagnosis of ALL and the effectiveness of the applied PCT remains not always predictable.

Particular attention deserves a separate subtype of T-ALL from early predecessors - ETP-ALL, which is characterized by a more severe course, which determines the difficulties both in diagnosis and in the introduction of patients.

Significant assistance in verifying the diagnosis of ETP-ALL is provided by the determination of surface cellular immunophenotypic markers using flow cytometry recommended by WHO, which makes it possible to determine both the diagnosis and the prognosis, as well as to choose an individual approach in planning the treatment of patients with ETP-ALL.

Conclusions:

1. Early immunophenotyping of blast cells makes it possible to timely correctly determine the variant of acute leukemia, and, in turn, start individualized targeted PCT, which allows achieving effective results in the treatment of patients with acute leukemia.

REFERENCES:

1. Anand P, Guillaumet-Adkins A, Dimitrova V, Yun H, Drier Y, Sotudeh N, et al. Single Cell RNA-Seq Reveals Developmental Plasticity with Coexisting

Oncogenic and Immune Evasion Programs in ETP-ALL. *Blood* (2021) 137(18): 2463–80. doi: 10.1182/blood.2019004547.

2. Arber DA, Orazi A, Hasserjian R, Thiele J, Borowitz MJ, Le Beau MM, et al. The 2016 Revision to the World Health Organization Classification of Myeloid Neoplasms and Acute Leukemia. *Blood* (2016) 127:2391–405. doi: 10.1182/blood-2016-03-643544.

3. Bayon-Calderon F, Toribio ML, Gonzalez-Garcia S. Facts and Challenges in Immunotherapy for T-Cell Acute Lymphoblastic Leukemia. *Int J Mol Sci* (2020) 21:1–35. doi: 10.3390/ijms21207685.

4. Bene M., Castoldi G., Knapp W., et al. Proposals for the immunological classification of acute leukemias. European Group for the Immunological Characterization of Leukemias (EGIL). *Leukemia*, 1995; 9(10): 1783-1786.

5. Bond J, Krzywon A, Lhermitte L, Roumier C, Roggy A, Belhocine M, et al. A Transcriptomic Continuum of Differentiation Arrest Identifies Myeloid Interface Acute Leukemias with Poor Prognosis. *Leukemia* (2021) 35:724–36. doi: 10.1038/s41375-020-0965-z.

6. Cancela, C. S. P., Murao, M., Assumpção, J. G., Souza, M. E. de L., de Macedo, A. V., Viana, M. B., & De Oliveira, B. M. (2017). Immunophenotyping of the cerebrospinal fluid as a prognostic factor at diagnosis of acute lymphoblastic leukemia in children and adolescents. *Pediatric Hematology and Oncology*, 34(2), 53–65. doi:10.1080/08880018.2017.1313920.

7. Coustan-Smith E, Mullighan CG, Onciu M, Behm FG, Raimondi SC, Pei D, et al. Early T-Cell Precursor Leukaemia: A Subtype of Very High-Risk Acute Lymphoblastic Leukaemia. *Lancet Oncol* (2009) 10:147–56. doi: 10.1016/S1470-2045(08)70314-0.

8. Dworzak MN, Buldini B, Gaipa G, Ratei R, Hrusak O, Luria D, et al. AIEOP-BFM Consensus Guidelines 2016 for Flow Cytometric Immunophenotyping of Pediatric Acute Lymphoblastic Leukemia. *Cytometry B Clin Cytom* (2018) 94:82–93. doi: 10.1002/cyto.b.21518.

9. Guru Murthy GS, Pondaiah SK, Abedin S, Atallah E. Incidence and Survival of T-Cell Acute Lymphoblastic Leukemia in the United States. *Leuk Lymphoma* (2019) 60:1171–8. doi: 10.1080/10428194.2018.1522442.

10. Jain N, Lamb AV, O'Brien S, Ravandi F, Konopleva M, Jabbour E, et al. Early T-Cell Precursor Acute Lymphoblastic Leukemia/Lymphoma (ETP-ALL/LBL) in Adolescents and Adults: A High-Risk Subtype. *Blood* (2016) 127:1863–9. doi: 10.1182/blood-2015-08-661702.

11. Khogeer H, Rahman H, Jain N, Angelova EA, Yang H, Quesada A, et al. Early T Precursor Acute Lymphoblastic Leukaemia/Lymphoma Shows Differential Immunophenotypic Characteristics Including Frequent CD33 Expression and *In Vitro* Response to Targeted CD33 Ther. *Br J Haematol* (2019) 186:538–48. doi: 10.1111/bjh.15960.

12. Morita K, Jain N, Kantarjian H, Takahashi K, Fang H, Konopleva M, et al. Outcome of T-Cell Acute Lymphoblastic Leukemia/Lymphoma: Focus on Near-ETP Phenotype and Differential Impact of Nelarabine. *Am J Hematol* (2021) 96:589–98. doi: 10.1002/ajh.26144.

13. Noronha EP, Marques LVC, Andrade FG, Sardou-Cezar I, Dos Santos-Bueno FV, Zampier CDP, et al. T-Lymphoid/Myeloid Mixed Phenotype Acute Leukemia and Early T-Cell Precursor Lymphoblastic Leukemia Similarities With NOTCH1 Mutation as a Good Prognostic Factor. *Cancer Manag Res* (2019) 11:3933–43. doi: 10.2147/CMAR.S196574.
14. Raetz EA, Teachey DT. T-Cell Acute Lymphoblastic Leukemia. *Hematol Am Soc Hematol Educ Program* (2016) 2016:580–8. doi: 10.1182/asheducation-2016.1.580.
15. Rafei H, Kantarjian HM, Jabbour EJ. Recent Advances in the Treatment of Acute Lymphoblastic Leukemia. *Leuk Lymphoma* (2019) 60:2606–21. doi: 10.1080/10428194.2019.1605071.
16. Sin C., Man P. M. Early T-cell precursor acute lymphoblastic leukemia: Diagnosis, updates in molecular pathogenesis, management, and novel therapies // *Frontiers in Oncology*.
17. Tavakoli Shirazi P, Eadie LN, Heatley SL, Hughes TP, Yeung DT, White DL. The Effect of Co-Occurring Lesions on Leukaemogenesis and Drug Response in T-ALL and ETP-ALL. *Br J Cancer* (2020) 122:455–64. doi: 10.1038/s41416-019-0647-7.
18. You MJ, Medeiros LJ, Hsi ED. T-Lymphoblastic Leukemia/Lymphoma. *Am J Clin Pathol* (2015) 144:411–22. doi: 10.1309/AJCPMF03LVSBLHPJ.
19. Zuurbier L, Gutierrez A, Mullighan CG, Cante-Barrett K, Gevaert AO, de Rooi J, et al. Immature MEF2C-Dysregulated T-Cell Leukemia Patients Have an Early T-Cell Precursor Acute Lymphoblastic Leukemia Gene Signature and Typically Have Non-Rearranged T-Cell Receptors. *Haematologica* (2014) 99:94–102. doi: 10.3324/haematol.2013.090233.